Mast Cell Involvement in Fibrodysplasia Ossificans Progressiva

FRANCIS H. GANNON, MD, DAVID GLASER, MD,
ROBERT CARON, MS, LESTER D.R. THOMPSON, MD,
EILEEN M. SHORE, PHD, AND FREDERICK S. KAPLAN, MD

Fibrodysplasia ossificans progressiva (FOP) is a catastrophic genetic disorder of progressive heterotopic ossification associated with dysregulated production of bone morphogenetic protein 4 (BMP4), a potent osteogenic morphogen. Postnatal heterotopic ossification in FOP is often heralded by hectic episodes of severe post-traumatic connective tissue swelling and intramuscular edema, followed by an intense and highly angiogenic fibroproliferative mass. The abrupt appearance, intense size, and rapid intrafascial spread of the edematous preosseous fibroproliferative lesions implicate a dysregulated wound response mechanism and suggest that cells and mediators involved in inflammation and tissue repair may be conscripted in the growth and progression of FOP lesions. The central and coordinate role of inflammatory mast cells and their mediators in tissue edema, wound repair, fibrogenesis, angiogenesis, and tumor invasion prompted us to investigate the potential involvement of mast cells in the pathology of FOP lesions. We show that inflammatory mast cells are present at every stage of the development of FOP lesions and are most pronounced at the highly vascular fibroproliferative stage. Mast cell density at the periphery of FOP lesional tissue is 40- to 150-fold greater than in normal control skeletal muscle or in uninvolved skeletal muscle from FOP patients and 10- to 40-fold greater than in any other inflammatory myopathy examined. These findings document mobilization and activation of inflammatory mast cells in the pathology of FOP lesions and provide a novel and previously unrecognized target for pharmacologic intervention in this extremely disabling disease. HUM PATHOL 32:842-848. This is a US government work. There are no restrictions on its use.

Key words: **mast cells, fibrodysplasia ossificans progressiva, heterotopic ossification, osteogenesis.**

Abbreviations: **FOP, fibrodysplasia ossificans progressiva; BMP4, bone morphogenetic protein 4; bFGF, basic fibroblast growth factor; VEGF, vascular endothelial growth factor; VPF, vascular permeability factor; TGF, transforming growth factor.**

Fibrodysplasia ossificans progressiva (FOP) is a rare autosomal dominant disorder characterized by congenital malformation of the great toes and by progressive heterotopic ossification in defined anatomic patterns.[1-3] Spontaneous and post-traumatic flare-ups of FOP are heralded by episodes of intense connective tissue edema with early histologic evidence of perivascular lymphocytic infiltration into skeletal muscle.[2-6] Highly angiogenic fibroproliferative lesions appear within hours, spread rapidly along muscle planes, and evolve through an endochondral ossification process to form mature lamellar bone.[2,7,8] Heterotopic ossification in FOP leads to immobilization of joints in the axial and appendicular skeleton, rendering movement impossible.[2,3,9,10] Death frequently results from starvation due to ankylosis of the jaw or from complications of severe restrictive disease of the chest wall.[2,3,11,12] Presently, there is no effective prevention or treatment.[13]

Although the genetic basis and pathophysiology of FOP are unknown, recent studies show overproduction of bone morphogenetic protein 4 (BMP4) in lesional lymphocytes, lesional proliferating fibroblasts, and lymphoblastoid cell lines from patients with FOP.[1,14-17] Additionally, elevated levels of urinary basic fibroblast growth factor (bFGF), a potent angiogenic peptide, are noted during FOP flare-ups but not during disease quiescence.[18] However, bFGF is not overproduced in lesional proliferating fibroblasts, implicating other cells as the source of bFGF. The intense soft tissue swelling and rapidly progressive muscle edema, fibroproliferation, and angiogenesis characteristic of early preosseous FOP lesions suggests involvement of an armada of inflammatory mediators at the leading edge of the lesion and points to a potential role for inflammatory mast cells in the spread of the disease process.

Mast cells mediate inflammatory reactions that are widely distributed in connective tissues. Mast cells arise from $CD34^+$ pluripotent stem cells of hematopoietic origin, circulate through the blood as committed but undifferentiated cells, and migrate into numerous tissues including skeletal muscle, where they mature in the presence of c-kit–ligand (stem cell factor).[19-27] Mast cells are indigenous to connective tissues and are found in close proximity to blood vessels and nerves.[28] In normal skeletal muscle, mast cells are found sparsely distributed in the connective tissue interstitium that

From the Departments of Orthopaedic Surgery, Genetics, and Medicine, the University of Pennsylvania School of Medicine, Philadelphia, PA; and the Departments of Orthopaedic Pathology and Otorhinolaryngology Pathology, the Armed Forces Institute of Pathology, Washington, DC. Accepted for publication April 30, 2001.

Supported by grants from the International Fibrodysplasia Ossificans Progressiva Association, the Center for Research in FOP and Related Disorders, the Ian Cali Fund, the Isaac & Rose Nassau Professorship of Orthopaedic Molecular Medicine, and the National Institutes of Health (2-RO1-AR-41916).

The opinions and assertions contained herein are the private views of the authors and are not to be construed as official or as reflecting the views of the Department of Defense.

Address correspondence and reprint requests to Frederick S. Kaplan, MD, Department of Orthopaedics, Division of Molecular Orthopaedics, Silverstein Two, The University of Pennsylvania Medical Center, 3400 Spruce St, Philadelphia, PA 19104.

This is a US government work. There are no restrictions on its use.

0046-8177/01/3208-0013$0.00/0
doi:10.1053/hupa.2001.26464

normally demarcates the fascicular structure of the muscle tissue.[29,30]

The cytoplasm of inflammatory mast cells contains prominent metachromatic granules whose sequestered contents include histamine, heparin, proangiogenic peptides, and extracellular matrix–degrading proteinases, including metalloproteinases, serine proteinases, chymases, acid hydrolases, and cathepsins.[21,25,26,31,32] Potent angiogenic peptides released by mast cells include bFGF, vascular endothelial growth factor (VEGF)/vascular permeability factor (VPF), and transforming growth factor β (TGF-β).[21,25,26,33-35] Mast cells also release a litany of proinflammatory molecules including tumor necrosis factor α, prostaglandin D_2, and numerous leukotrienes.[21,25,26,28,36,37] Upon release from the mast cells, these substances influence a vast array of physiologic processes, including focal and neurogenic inflammation, immunomodulation, angiogenesis, fibrogenesis, extracellular matrix remodeling, tissue repair, and tumor invasion.[21,24-26,38-40]

The intense muscle edema and rapid spread of the preosseous fibroproliferative FOP lesions along muscle planes suggests a potential role for mast cells in the progression of the disease process. However, mast cells are not easily identifiable with routine hematoxylin–eosin staining and have not been previously recognized or described in FOP pathology.

Little is known about the resident mast cell population in skeletal muscle. We have undertaken a comprehensive analysis of mast cell distribution in normal skeletal muscle, in uninvolved skeletal muscle from patients with FOP, in FOP lesions, and in inflammatory myopathies to determine if mast cells may be involved in the pathology of FOP lesions.

MATERIALS AND METHODS

Patient Population

Between 1988 and 1999, 174 patients with classic features of FOP were referred to the FOP clinic at the University of Pennsylvania School of Medicine and were seen at the Children's Hospital of Philadelphia, at the Hospital of the University of Pennsylvania, or at one of the satellite clinics conducted by 2 of us (F.S.K. and D.L.G.). A definitive diagnosis of FOP was confirmed in all 174 patients on the basis of congenital malformation of the great toes and progressive heterotopic ossification in characteristic anatomic patterns. FOP protocols were approved by the institutional review boards of the Children's Hospital of Philadelphia and the University of Pennsylvania, and informed consent was obtained from all patients or their parents.

FOP Biopsy Specimen Retrieval

All FOP lesional tissue was retrieved from the tissue repository at the Center For Research in FOP and Related Disorders at The University of Pennsylvania. Tissue blocks were originally procured after patient or parental permission was obtained. All lesional samples contained in the database were used. At the time of the study, paraffin-embedded tissue blocks of FOP lesions were available from 7 of the 174 classically affected FOP patients. Multiple blocks of the lesions were available for 3 of the 7 patients (4 girls and 3 boys), who ranged in age from 1 to 10 years at the time of the biopsies. Samples were obtained from fibrous tissue in deep fascia and from paravertebral, infraspinatus, frontalis, sternocleidomastoid, vastus lateralis, and intercostal muscles. All specimens had been resected by means of an open biopsy of lesional tissue. The FOP lesional biopsies had been performed at other medical centers to exclude the diagnosis of a soft tissue neoplasm, and in none of the cases was the correct diagnosis suspected before surgery. FOP nonlesional muscle tissue was obtained from 3 children with FOP who underwent emergency surgical procedures for intercurrent problems.

Inflammatory Muscle Conditions

Specimens from normal control muscle tissue and genetic and nonparasitic inflammatory myopathies were retrieved from the files of the Armed Forces Institute of Pathology during the period of 1996 through 1998. One hundred six cases were included in the analysis and involved a variety of muscle groups (quadraceps, deltoid, mandible, omohyoid, biceps, trapezius, sternocleidomastoid, gastrocnemius, scalenus, rectus, vastus lateralis, tibialis anterior, and diaphragm) and the following conditions: minimal inflammation,[71] severe inflammatory myopathy,[15] polymyositis,[5] dermatomyositis,[4] acute infection,[4] scar,[2] tumor invading into muscle,[2] foreign body,[1] infarct,[1] and pan necrosis.[1] A total of 62 men and 44 women ranging in age from 1 to 78 years were represented in this series.

Tissue Specimens and Histopathologic Evaluations

All tissue specimens had been fixed in neutral buffered formalin and embedded in paraffin. Specimens were sectioned at a thickness of 5 μm and stained with hematoxylin–eosin, toluidine blue, Giemsa, and chloracetate esterase stains. The histochemical stains were performed according to standard protocols. Chloracetate esterase staining was performed on all of the FOP (both lesional and nonlesional) specimens and all of the control muscle samples. A Giemsa stain was also performed on all of the FOP tissue and 26 of the control muscle samples. The chloracetate esterase–stained specimens were used to score mast cells and for photographic purposes because of the ease of differentiation of mast cells with this stain. All slides were examined under light microscopy by 2 investigators (F.H.G. and L.D.R.T.). Each of the stained sections was examined at high magnification (40×), and mast cells were counted in 10 high-power fields. Five

TABLE 1. Mast Cell Density in Normal Skeletal Muscle, Inflammatory Myopathies, and Fibrodysplasia Ossificans Progressiva Lesions

Tissue	Mast Cells/10 HPF
Normal skeletal muscle	≤0.1
Inflammatory myopathies	0.1-0.3
FOP uninvolved skeletal muscle	≤0.1
FOP lesional tissue	
Stage 1A	1-2
Stage 1B	1-2
Stage 1C	4-15
Stage 2A	4-15
Stage 2B	1-4
Stage 2C	1

Abbreviation: HPF, high-power field.

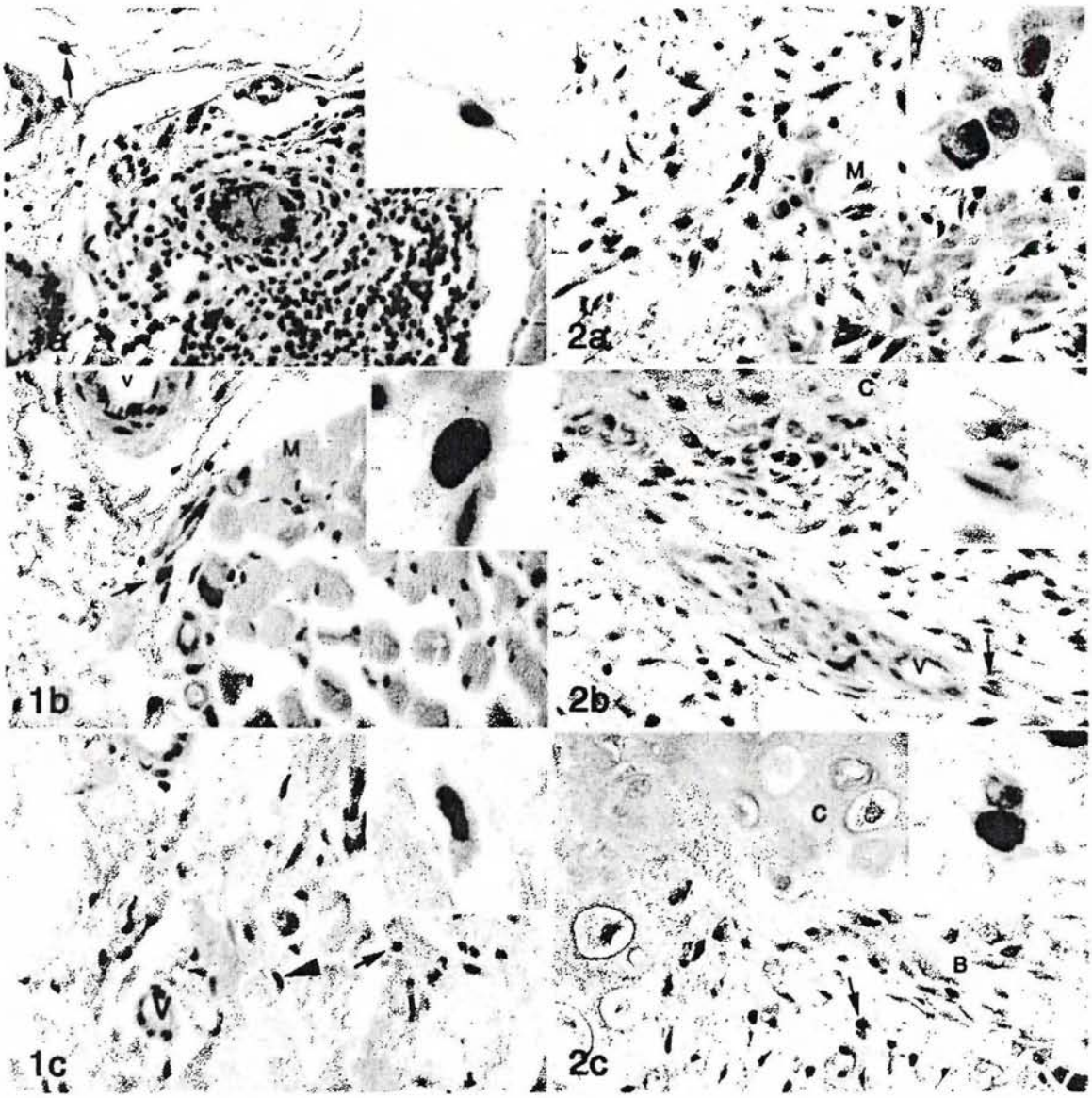

FIGURE 1. Mast cell mobilization in FOP lesions: (panels 1a, 1b, and 1c) mast cells in early stages of FOP lesion formation; (panels 2a, 2b, and 2c) mast cells in later stages of FOP lesion formation. (Panel 1a) High-power photomicrograph of the earliest lesion of FOP (stage 1A). Lymphocytes surround a vessel (V) with a mast cell (arrow) in the surrounding connective tissue. The arrow points to the mast cell shown in the inset. (Chloracetate esterase staining; original magnification ×480; inset, original magnification ×1,600.) (Panel 1b) High-power field of a stage 1B FOP lesion. This next phase of progression reveals myocytes (M) with admixed myonecrosis and an adjacent mast cell (arrow). A vessel (V) is also noted. The arrow points to the mast cell shown in inset. (Chloracetate esterase staining; original magnification ×480; inset, original magnification ×1,600.) (Panel 1c) High-power photomicrograph of a stage 1C FOP lesion. This stage exhibits an early fibroproliferative lesion with abundant mast cells (arrow and arrowhead). The arrowhead points to the mast cell shown in the inset. (Chloracetate esterase staining; original magnification ×480; inset, original magnification ×1,600.) (Panel 2a) A stage 2A fibroproliferative lesion with vessels (V), fibroconnective tissue, and mast cells. M, myocytes. (Chloracetate esterase staining; original magnification ×480; inset, original magnification ×1,600.) (Panel 2b) A high-power field of a stage 2B fibroproliferative lesion showing cartilage (C) production, vessels (V) and a mast cell (arrow) adjacent to a vessel. The arrow points to the mast cell shown in the inset. (Chloracetate esterase staining; original magnification ×480; inset, original magnification ×1,600.) (Panel 2c) A high-power photomicrograph of a mature FOP lesion (stage 2C) shows bone (B) and cartilage (C) and a nearby mast cell (arrow) The arrow points to the mast cell shown in the inset. (Chloracetate esterase staining; original magnification, ×480; inset, original magnification ×1,600.)

FIGURE 2. Hypothetical schema of pathophysiology of FOP lesions. Although mast cell involvement is unlikely to be responsible for formation of fibroproliferative lesions, mast cells may potentiate the severity of the inflammatory response and thus progressive spread of a lesion along tissue planes. FOP patients are genetically susceptible to BMP4-mediated heterotopic ossification.

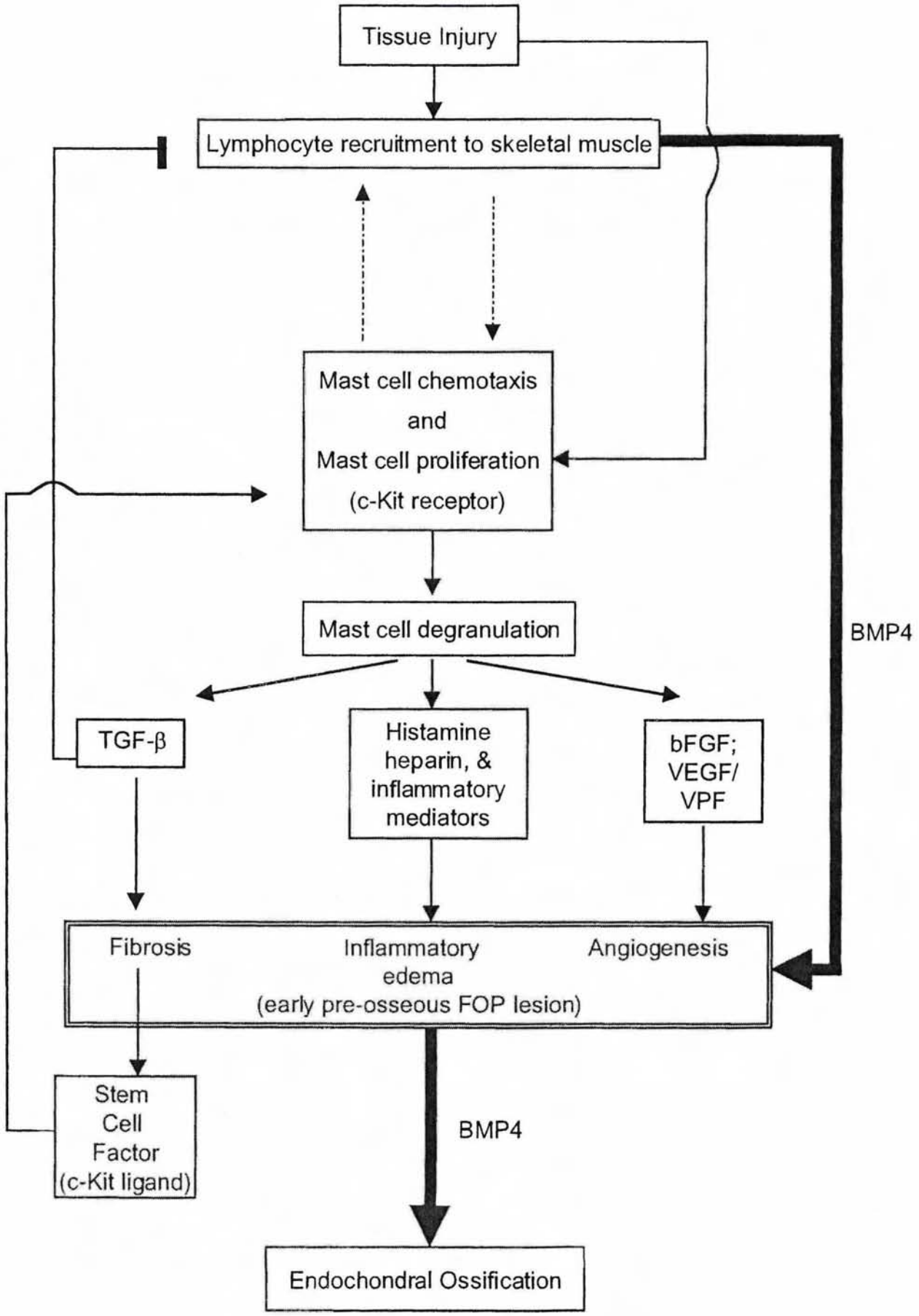
Tissue Injury
Lymphocyte recruitment to skeletal muscle
Mast cell chemotaxis
and
Mast cell proliferation
(c-Kit receptor)
Mast cell degranulation
BMP4
TGF-β
Histamine
heparin, &
inflammatory
mediators
bFGF;
VEGF/
VPF
Fibrosis
Inflammatory
edema
Angiogenesis
(early pre-osseous FOP lesion)
Stem
Cell
Factor
(c-Kit ligand)
BMP4
Endochondral Ossification

groups of 10 high-power fields were counted in the muscle controls, and between 5 and 10 groups of 10 high-power fields were counted for the FOP tissue depending on the size of the biopsy specimen. Each of the pathologists (F.H.G. and L.D.R.T.) performed these counts individually, and the results were averaged. The starting point for the analysis was randomly chosen, but all fields were contiguous and within the lesional tissue. The counting was repeated on separate occasions to determine intraobserver and interobserver variation. Mast cells were identified as indigenous connective tissue cells with large central nuclei and large abundant metachromatic cytoplasmic granules when stained by cationic dyes, such as toluidine blue or Giemsa (because of the presence of sulfated glycosaminoglycans) or when stained by chloracetate esterase (because of the presence of chymotrypsin-like serine esterase activity). Intraobserver variation was <1%, and interobserver variation was 3%.

RESULTS

Mast Cells in Normal Muscle

Representative muscle groups were examined from axial, appendicular, cranial, truncal, caudal, dorsal, ventral, proximal, and distal regions of the body (Table 1). There was a remarkably consistent distribution and low density of mast cells in normal skeletal muscle from all anatomic sites and across all age ranges. There were no differences in the pattern or density of mast cell distribution between uninvolved skeletal muscle from normal controls and uninvolved skeletal muscle from patients with FOP (Table 1). Mast cells were limited in distribution to the connective tissue interstitium of normal skeletal muscle and uninvolved FOP muscle at a density of ≤0.1 mast cells per 10 high-power fields (Table 1).

Mast Cells in Inflammatory Myopathies

Mast cell density in inflammatory myopathies ranged from 0.1 to 0.3 mast cells per 10 high-power fields, regardless of the underlying etiology of the myopathic process (Table 1). Similar to normal skeletal muscle, the mast cells in inflammatory myopathies were limited to the interstitium in the majority of cases, with an occasional mast cell noted within the surrounding muscle.

Mast Cells in FOP Lesions

FOP lesions were staged histologically based on the pathologic and morphologic characteristics and have been designated 1A, 1B, 1C, 2A, 2B, and 2C as previously described.[6] The 1A lesion (Fig 1, panel 1a) is characterized by an intense perivascular B-cell and T-cell lymphocytic aggregation before invasion into the surrounding muscle tissue. Even at this early stage, mast cells are associated with perivascular lymphocytic infiltrates and are 10-fold more abundant (1.0 mast cells per 10 high-power fields) than in normal control skeletal muscle. In stage 1B lesions (Fig 1, panel 1b), T lymphocytes have migrated from the perivascular space into the surrounding muscle. At this stage, mast cells are mobilized from the perivascular connective tissue interstitium of the dying skeletal muscle and are at a significantly higher concentration than in normal control muscle tissue at any site in the body (Table 1). Stage 1C lesions are characterized by the first appearance of a vascular fibroproliferative tissue (Fig 1, panel 1c) that surrounds and invades the contiguous skeletal muscle. Mast cells are noted in abundance at this stage with a tissue density of 4 to 15 mast cells per 10 high-power fields, 40- to 150-fold greater than the density observed in normal skeletal muscle and nonlesional FOP muscle, and 10- to 40-fold greater than that observed in any of the inflammatory myopathies (Table 1).

As an FOP lesion progresses into stage 2A (Fig 1, panel 2a), a highly monotonous vascular and edematous fibroproliferative lesion is noted. Mast cells are noted in abundance at the leading edge and around the periphery of the fibroproliferative lesion at a density indistinguishable from that of the 1C lesion. Stage 2B FOP lesions are identified by the first appearance of cartilage (Fig 1, panel 2b), and the mast cells are generally confined to the fibrous pseudocapsule surrounding the cartilage. In stage 2C, the mature stage of the FOP lesion, endochondral ossification is noted (Fig 1, panel 2c). At this stage, mast cells are noted only at the periphery of the lesion at a density that is similar to that of the early stage 1A lesion (Table 1) but still 10-fold higher than in uninvolved skeletal muscle. However, at this stage, there is no longer any residual histologic presence of muscle; the previously existing skeletal muscle tissue has been replaced by bone.

DISCUSSION

The most significant finding of our study was the dramatic mobilization and activation of inflammatory mast cells at all stages of FOP lesional development. These data document an unanticipated and previously unrecognized presence of mast cells in the pathology of FOP lesions. Mast cells have long been known to be involved in bone remodeling, but this is the first report to implicate their involvement in de novo osteogenesis.[41]

Recent studies have elucidated conditions, such as disruption of the myofiber membrane, that induce mast cell accumulation in skeletal muscle.[20] In an injured muscle, peak mast cell accumulation occurs at the onset of regeneration, approximately 3 days after experimental phospholipase injection or 11 days after ischemic injury, but not during the phase of muscle necrosis.[20,42] The pattern of mast cell infiltration in FOP lesions is qualitatively different from these findings and shows a steady progression of the mast cell numbers and association with myonecrosis and neoangiogenesis. The appearance of mast cells in FOP lesions is thus qualitatively different from that seen in a variety of inflammatory myopathies and quantitatively much more intense.

Mast cells play a prominent role in the local invasion of tumors.[43] Mast cells accumulate at the leading

edge of invading carcinomas, where they are conscripted for angiogenesis and local tumor invasion, but mast cells are not found in the core of the invading tumors.[43] In FOP, mast cells are found in abundance predominantly at the leading edge of the more mature FOP lesions (stages 2A to 2C) and within the lesions themselves at the earlier, less mature stages (1A to 1C).

Mast cells discharge their stored granules into the interfascicular matrix of skeletal muscle upon exposure to a wide variety of immunologic or external stimula, including thermal or mechanical trauma and T cell–mediated inflammatory processes.[29,30,44] T cell–mast cell interactions are intimate, bidirectional, and robust.[45,46] Mast cells are able to present antigens to T cells, and mast cell–derived cytokines such as interleukin 4 stimulate T cells to differentiate into various T-cell subsets.[46,47] Conversely, T cell–derived mediators directly induce mast cell degranulation.[46,48] The intimate temporal and spatial relationship of lymphocytes and mast cells in the FOP lesions lends additional support to the cooperative interaction of these hematopoietically derived cell types.

Our findings provide an intriguing model for the pathophysiology of FOP lesions that builds upon our earlier knowledge (Fig 2). Cells in FOP are genetically conditioned toward a bone induction response, and lymphocytic infiltration of early FOP lesions has been observed. We hypothesize that tissue injury in FOP leads to lymphocyte migration into skeletal muscle.[6,14] Subsets of lesional lymphocytes overproduce BMP4 and lead to mast cell mobilization, a finding supported strongly by the FOP pathology and by models of bone morphogenetic protein–induced heterotopic ossification[6,49] (Glaser et al, manuscript in preparation). Mediators released by degranulating mast cells stimulate a re-entrant cycle of inflammatory edema, fibrosis, and angiogenesis potentiated at the leading edge of an advancing FOP lesion. Reactive fibroblasts produce stem cell factor, which leads to further proliferation of mast cells and a self-sustaining escalation of the disease process known as a flare-up. Eventually, TGF-β released by mast cells and other lesional cells modulates the lymphocytic recruitment and migration, while endogenous overexpression of BMP4 in the fibroproliferative core drives the fibroproliferative lesion toward ossification through an endochondral pathway, regardless of the presence of mast cells (Fig 2).

At present, no animal models of FOP mimic the flagrant tissue edema and the rapid spread of a preosseous fibroproliferative lesion along tissue planes. The presence of a normal skeleton in mast cell–deficient animals and the paucity of mast cells in experimental fracture healing suggest that mast cells are not necessary either for the embryonic formation and maturation of skeletal elements or for the repair of fractures.[43,50] Furthermore, mast cell–deficient animals form heterotopic bone after BMP implantation (Glaser, manuscript in preparation). Just as mast cells play an important role in tissue invasion of precancerous lesions, mast cells may promote invasive osteogenic lesions such as FOP.[43] To determine whether mast cells play a role in the spread of FOP lesions, a controlled clinical trial of mast cell inhibitors may be warranted in patients with FOP.[51,52] The observation of mast cell mobilization in FOP lesions provides a novel and previously unrecognized opportunity to evaluate anti–mast cell therapies in FOP.

Acknowledgement. The authors thank Veronica Ferris, MFS, for her fine photography.

REFERENCES

1. Kaplan FS, Tabas JA, Zasloff MA: Fibrodysplasia ossificans progressiva: A clue from the fly? Calcif Tissue Int 47:117-125, 1990

2. Cohen RB, Hahn GV, Tabas JA, et al: The natural history of heterotopic ossification in patients who have fibrodysplasia ossificans progressiva. A study of forty-four patients. J Bone Joint Surg [Am] 75:215-219, 1993

3. Connor JM, Evans DAP: Fibrodysplasia ossificans progressiva. The clinical features and natural history of 34 patients. J Bone Joint Surg [Br] 64:76-83, 1982

4. Lanchoney TF, Cohen RB, Rocke DM, et al: Permanent heterotopic ossification at the injection site after diphtheria-tetanus-pertussis immunizations in children who have fibrodysplasia ossificans progressiva. J Pediatr 126:762-764, 1995

5. Luchetti W, Cohen RB, Hahn GV, et al: Severe restriction in jaw movement after routine injection of local anesthetic in patients who have fibrodysplasia ossificans progressiva. Oral Surg Oral Med Oral Pathol 81:21-25, 1996

6. Gannon FH, Valentine BA, Shore EM, et al: Acute lymphocytic infiltration in extremely early lesions of fibrodysplasia ossificans progressiva. Clin Orthop 346:19-25, 1998

7. Kaplan FS, Tabas JA, Gannon FH, et al: The histopathology of fibrodysplasia ossificans progressiva. An endochondral process. J Bone Joint Surg [Am] 75:220-230, 1993

8. Moriatis JM, Gannon FH, Shore EM, et al: Limb swelling in patients who have fibrodysplasia ossificans progressiva. Clin Orthop 336:247-253, 1997

9. Kaplan FS, Strear CM, Zasloff MA: Radiographic and scintigraphic features of modeling and remodeling in the heterotopic skeleton of patients who have fibrodysplasia ossificans progressiva. Clin Orthop 304:238-247, 1994

10. Shah PB, Zasloff MA, Drummond D, et al: Spinal deformity in patients who have fibrodysplasia ossificans progressiva. J Bone Joint Surg [Am] 76:1442-1450, 1994

11. Kussmaul WG, Esmail AN, Sagir Y, et al: Pulmonary and cardiac function in advanced fibrodysplasia ossificans progressiva. Clin Orthop 346:104-109, 1998

12. Janoff H, Cohen R, Shafritz A, et al: Submandibular swelling in patients who have fibrodysplasia ossificans progressiva: A life threatening complication. J Bone Miner Res 9:S428, 1994

13. Kaplan FS, Shore EM, Zasloff MA: Fibrodysplasia ossificans progressiva: searching for the skeleton key. Calcif Tissue Int 59:75-78, 1996

14. Shafritz AB, Shore EM, Gannon FH, et al: Overexpression of an osteogenic morphogen in fibrodysplasia ossificans progressiva. N Engl J Med 335:555-561, 1996

15. Gannon FH, Kaplan FS, Olmsted E, et al: Bone morphogenetic protein (BMP) 2/4 in early fibromatous lesions of fibrodysplasia ossificans progressiva. Hum Pathol 28:339-343, 1997

16. Lanchoney TF, Olmsted EA, Shore EM, et al: Characterization of bone morphogenetic protein-4 receptors in fibrodysplasia ossificans progressiva. Clin Orthop 346:38-45, 1998

17. Roush W: Protein builds second skeleton. Science 273:1170, 1996

18. Kaplan FS, Sawyer J, Connors S, et al: Urinary basic fibroblast growth factor: A biochemical marker for pre-osseous fibroproliferative lesions in patients who have fibrodysplasia ossificans progressiva. Clin Orthop 346:59-65, 1998

19. Kirshenbaum AS, Kessler SW, Goff JP, et al: Demonstration

of the origin of human mast cells from CD34+ bone marrow progenitor cells. J Immunol 146:1410-1415, 1991

20. Lefaucheur JP, Gjata B, Sebille A: Factors inducing mast cell accumulation in skeletal muscle. Neuropathol Appl Neurobiol 22: 248-255, 1996

21. Galli SJ: Mast cells and basophils. Curr Opin Hematol 7:32-39, 2000

22. Rottem M, Okada T, Goff JP, et al: Mast cells cultured from the peripheral blood of normal donors and patients with mastocytosis originate from a CD34+/Fc epsilon RI- cell population. Blood 84: 2489-2496, 1994

23. Dastych J, Metcalfe DD: Stem cell factor induces mast cell adhesion to fibronectin. J Immunol 152:213-219, 1994

24. Thompson HL, Burbelo PD, Gabriel G, et al: Murine mast cells synthesize basement membrane components. A potential role in early fibrosis. J Clin Invest 87:619-623, 1991

25. Metcalfe DD, Baram D, Mekori YA: Mast cells. Physiol Rev 77:1033-1079, 1997

26. Nilsson G, Metcalfe DD: Contemporary issues in mast cell biology. Allergy Asthma Proc 17:59-63, 1996

27. Metcalfe DD: Interaction of mast cells with extracellular matrix proteins. Int Arch Allergy Immunol 107:60-62, 1995

28. Galli SJ: New concepts about the mast cell. N Engl J Med 328:257-265, 1993

29. Nahirney PC, Dow PR, Ovalle WK: Quantitative morphology of mast cells in skeletal muscle of normal and genetically dystrophic mice. Anat Rec 247:341-349, 1997

30. Helliwell TR, Gunhan O, Edwards RH: Mast cells in neuromuscular diseases. J Neurol Sci 98:267-276, 1990

31. Blair RJ, Meng H, Marchese MJ, et al: Human mast cells stimulate vascular tube formation. Tryptase is a novel, potent angiogenic factor. J Clin Invest 99:2691-2700, 1997

32. Humphries DE, Wong GW, Friend DS, et al: Heparin is essential for the storage of specific granule proteases in mast cells. Nature 400:769-772, 1999

33. Grutzkau A, Kruger-Krasagakes S, Baumeister H, et al: Synthesis, storage, and release of vascular endothelial growth factor/vascular permeability factor (VEGF/VPF) by human mast cells: Implications for the biological significance of VEGF206. Mol Biol Cell 9:875-884, 1998

34. Lefaucheur JP, Gjata B, Lafont H, et al: Angiogenic and inflammatory responses following skeletal muscle injury are altered by immune neutralization of endogenous basic fibroblast growth factor, insulin-like growth factor-1 and transforming growth factor-beta 1. J Neuroimmunol 70:37-44, 1996

35. Olsson N, Piek E, ten Dijke P, et al: Human mast cell migration in response to members of the transforming growth factor-beta family. J Leukoc Biol 67:350-356, 2000

36. Marone G, Casolaro V, Patella V, et al: Molecular and cellular biology of mast cells and basophils. Int Arch Allergy Immunol 114:207-217, 1997

37. Awad JA, Morrow JD, Roberts LJ 2nd: Detection of the major urinary metabolite of prostaglandin D2 in the circulation: Demonstration of elevated levels in patients with disorders of systemic mast cell activation. J Allergy Clin Immunol 93:817-824, 1994

38. Gruber BL, Kew RR, Jelaska A, et al: Human mast cells activate fibroblasts: tryptase is a fibrogenic factor stimulating collagen messenger ribonucleic acid synthesis and fibroblast chemotaxis. J Immunol 158:2310-2317, 1997

39. Norrby K, Wooley DE: Role of mast cells in mitogenesis and angiogenesis in normal tissue and tumor tissue. Adv Biosci 89:71-115, 1993

40. Steinhoff M, Vergnolle N, Young SH, et al: Agonists of proteinase-activated receptor 2 induce inflammation by a neurogenic mechanism. Nature 6:151-158, 2000

41. McKenna MJ, Frame B: The mast cell and bone. Clin Orthop 200:226-233, 1985

42. Rafael J, Gorospe M, Nishikawa BK, Hoffman EP: Recruitment of mast cells to muscle after mild damage. J Neurol Sci 135:10-17, 1996

43. Coussens LM, Raymond WW, Bergers G, et al: Inflammatory mast cells up-regulate angiogenesis during squamous epithelial carcinogenesis. Genes Dev 13:1382-1397, 1999

44. Gorospe JR, Tharp MD, Hinckley J, et al: A role for mast cells in the progression of Duchenne muscular dystrophy? Correlations in dystrophin-deficient humans, dogs, and mice. J Neurol Sci 122:44-56, 1994

45. Frieri M, Metcalfe DD: Analysis of the effect of mast cell granules on lymphocyte blastogenesis in the absence and presence of mitogens: Identification of heparin as a granule-associated suppressor factor. J Immunol 131:1942-1948, 1983

46. Mekori YA, Metcalfe DD: Mast cell-T cell interactions. J Allergy Clin Immunol 104:517-523, 1999

47. Tkaczyk C, Villa I, Peronet R, et al: In vitro and in vivo immunostimulatory potential of bone marrow-derived mast cells on B- and T-lymphocyte activation. J Allergy Clin Immunol 105:134-142, 2000

48. Bhattacharyya SP, Drucker I, Reshef T, et al: Activated T lymphocytes induce degranulation and cytokine production by human mast cells following cell-to-cell contact. J Leukoc Biol 63:337-341, 1998

49. Glaser D, Gannon F, Kaplan F, et al: Characterization of the earliest stages of post-natal endochondral ossification. J Bone Min Res 12: F296, 1997 (suppl 1)

50. Taniguchi H: Mast cells in fracture healing: An experimental study using rat model. Nippon Seikeigeka Gakkai Zasshi 64:949-957, 1990

51. Barnes PJ: Therapeutic strategies for allergic diseases. Nature 402:B31-B38, 1999

52. Finotto S, Mekori YA, Metcalfe DD: Glucocorticoids decrease tissue mast cell number by reducing the production of the c-kit ligand, stem cell factor, by resident cells: In vitro and in vivo evidence in murine systems. J Clin Invest 99:1721-1728, 1997